

CLINICAL TECHNIQUES

Evaluation and Result of Reduction Labioplasty

Allen Rezai, MD; Per-Erik Jansson, MD

Hypertrophy and variation in the size of labia minora have long been recognized. Hypertrophic labia minora can be bothersome for aesthetic, functional, and psychosocial reasons. The hypertrophy includes both width and length of the labia minora, and it can be congenital^{1,2} or acquired by chronic irritations, excessive masturbation, and abnormal participation in sexual activities.³ The indications that this can cause are local irritation, poor hygiene, interference with sexual intercourse, and intermittent urination.^{1,2,4} In the past, labia minora reduction was usually performed by a simple and straight resection of the protuberant segment and oversewing the edge.^{1,2,4} This technique would often result in postoperative discomfort and complication. However, over the years, the treatment of this problem has been improved by using the w-shaped method and central de-epithelialization of the labia minora. We have performed both the w-shaped technique and the de-epithelialized reduction labioplasty.

Twenty-three patients underwent treatment of hypertrophic labia minora with excellent result and minimal postoperative discomfort. From our study, we realized that the de-epithelialized reduction labioplasty gives the patient more satisfaction both in the appearance of the edge of the labia minora and the neurovascular preservations of the labia.

Materials and Methods

From March 1997 to February 2005, 100 women, aged 17 to 45 years, underwent reduction labioplasty. Indications for the operation were both functional and aesthetic problems (Table).

Operations were performed using both general (25 patients) and local (75 patients) anesthesia. All patients

were examined preoperatively in the lithotomy position with visualization of hair genitalia and considerations given to their problems and labia minor abnormality (Figure 1).

We performed w-shaped resections of the protuberant segment with interdigitated suturing in 50 cases (group A) and de-epithelialized reduction labioplasty in 50 cases (group B). All patients were marked in the lithotomy position before receiving anesthesia. Patients who chose to undergo the operation under local anesthesia and sedation received a single intravenous dose of midazolam 1 mg/mL and alfentanil 0.5 mg/mL under cardiopulmonary monitoring. Then, in both groups, the medial and lateral parts of each labia minor were injected with 1% lidocaine and adrenalin (1:200 000) to decrease bleeding and increase the subcutaneous space between the lateral and medial parts of the labium, which also made the de-epithelialization easier (Figure 2).

In group A, we performed the method with a running w-shaped resection on the medial aspect of each labia minus with concern to not extend the incision dorsally into the posterior fourchette and ventrally beyond the base of the frenulum (Figure 3A and 3B).^{4,5} After the resection of excessive parts of the labia minor on each side and homeostasis, the thin edge of the labia minus was sutured with Monocryl 5-0 (Johnson & Johnson, Brussels, Belgium).

In group B, we performed labia minor reduction by de-epithelialization of the central portions and reapproximation of the edges of the labia minus, according to the technique of Choi and Kim⁶ (Figure 4A through 4C).

The de-epithelialization was done on both sides of the labia minus and after the removal of the de-epithelialized tissue, and the edges were reapproximated by running sutures with Monocryl 5-0 (Johnson & Johnson; Figure 4C).

In both groups, the width of the labia was kept at about 1 cm, and no vaginal packing or urinary catheterization was needed.

Received for publication January 9, 2007.
From Cosmetic Surgery Specialists, London, UK.
Corresponding author: Allen Rezai, MD, 40 Harley St, London W1G 9PP, UK (e-mail: allenrezaimd@bulldoghome.com).

Functional and Aesthetic Indications for Undergoing Labia Minora Reduction in 100 Patients*

Indication	Patients
Interference with sexual intercourse	25
Interference with physical activity (eg, riding horse or bicycle)	16
Aesthetic concerns (eg, labia sticking out under underwear)	55
Poor hygiene	15
Intermittent urinary	17

*Most patients had more than 1 indication.

Results

Patients in both groups had minimal discomfort postoperatively (except for 3 patients who suffered from postoperative infection, which was treated with antibiotics) and were satisfied with the appearance after 6 weeks. The 6-month postoperative review indicated that patients in both groups experienced improvement of chronic irritations, sexual intercourse, hygiene, and the relief of their cardinal problems. However, in group A, 5 patients were not satisfied with the appearance of the edge of the labia minora, and in 8 patients, it took up to 2 years for

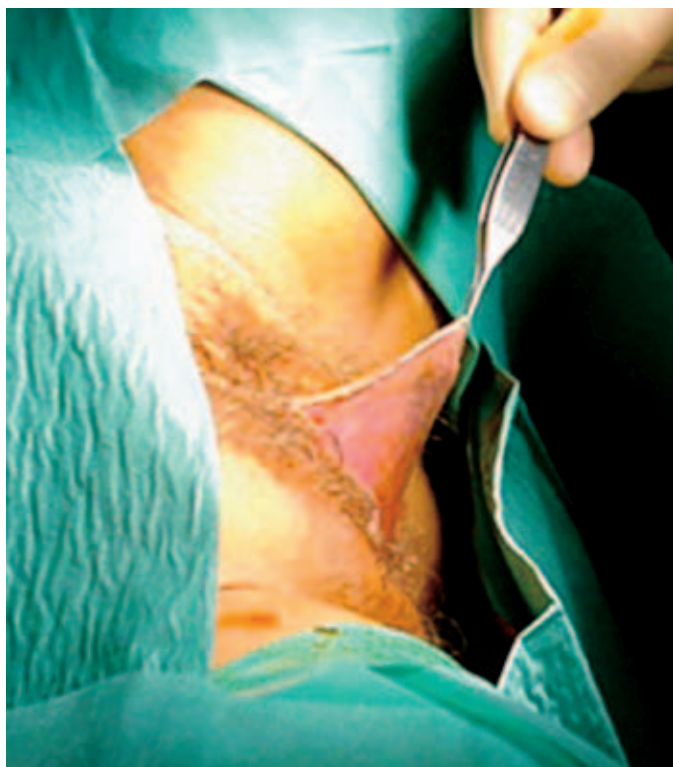


Figure 1. Enlarged size of labia minora with the patient in a lithotomy position.

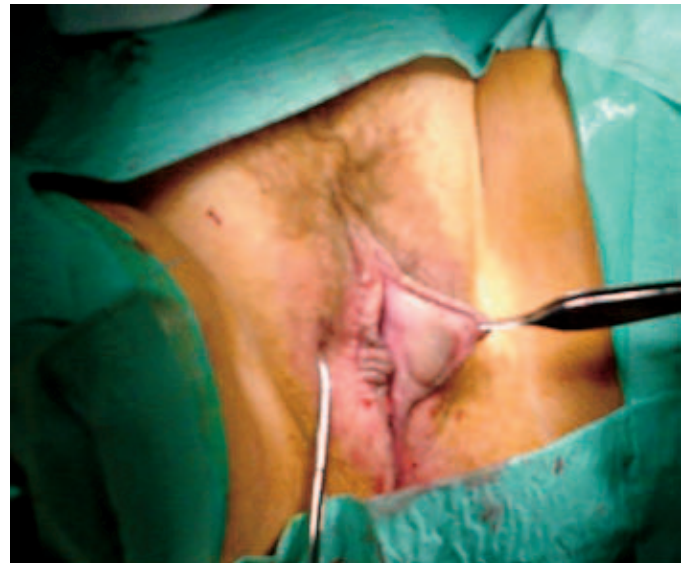

Figure 2. After marking and injection of local anesthesia.

sensation to be restored to the labia minora. The follow-up range is from 2 months to 2 years (Figures 3B and 4C).

Discussion

Hypertrophy and variation in the size of the labia minora has long been recognized.⁵ The hypertrophy includes both the width and length of the labia minora, and it can be congenital, as described by Capraro¹ and Radman.² However, other cases of labia hypertrophy including granulomatous disease, myelodysplastic disease, vulvar lymphoedema, topical and systematic hormones, mechanical irritations, masturbation, and abnormal participations in sexual activity have also been described as reasons for this problem. The reduction of hypertrophic labia minora offers women physical and psychological comfort.⁴ Over the years, treatment of this problem has been varied from simple resections of the protuberant segment of the hypertrophic labium to excising a wedge of protuberant labia tissue and replacing it with a thin, irregular suture line, as Alter⁵ has described.

Surgeons have modified Alter's technique through the years by using Z-plasty, w-shaped technique, and central de-epithelialization of labia minor to prevent longitudinal scar contractions and to preserve the natural edge of the labia.

Conclusions

From this study, we have realized that de-epithelialized reduction labioplasty gives the patient more satisfaction

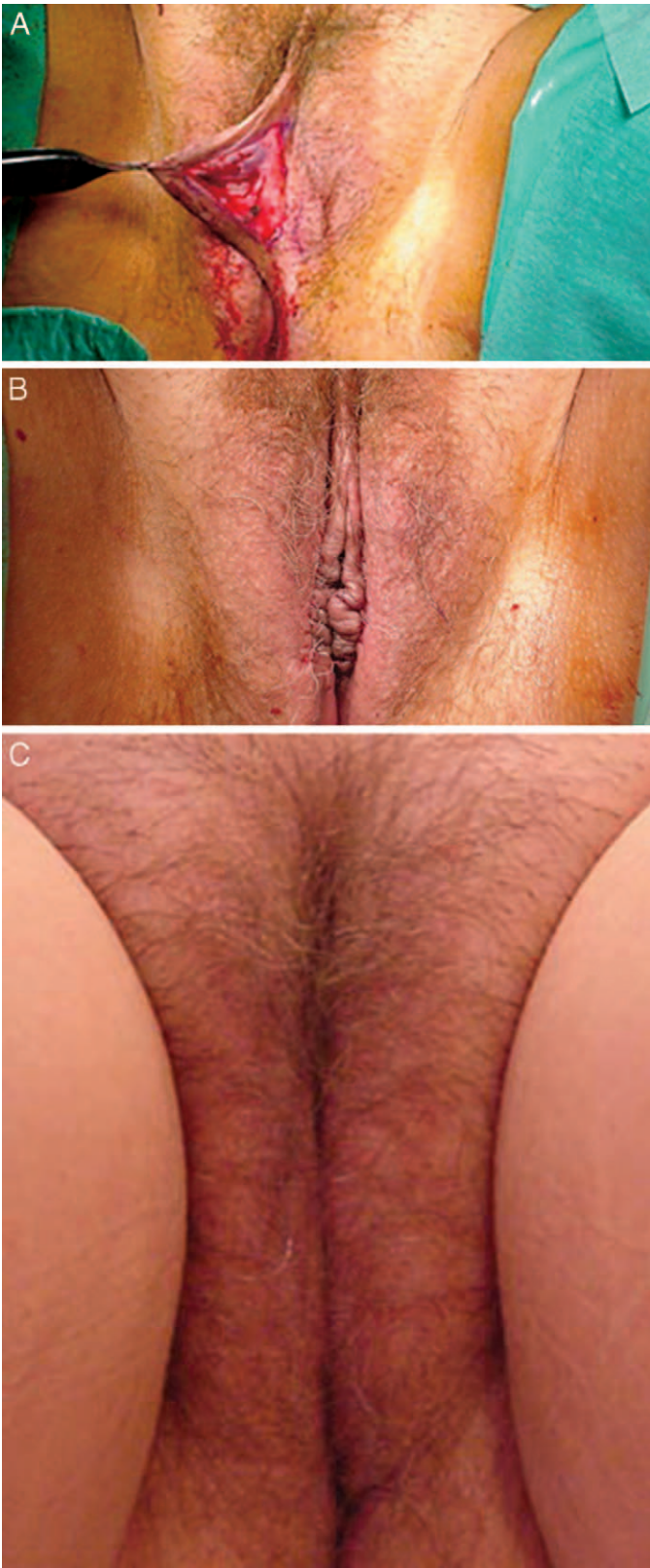


Figure 3. (A) De-epithelialization was done, and the tissue was removed. (B) After reapproximation of the margins by running sutures. (C) Two months postoperative result after using the de-epithelialization technique.

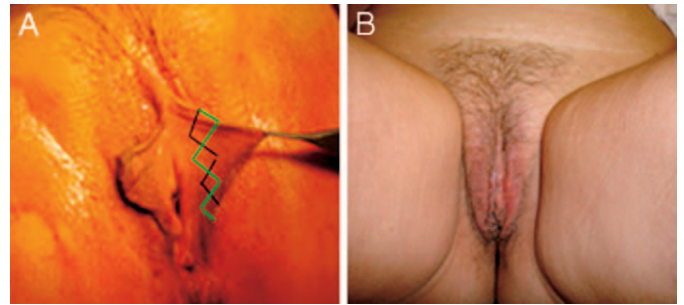


Figure 4. (A) After marking for running w-shaped incision. The black line indicates incision on the medial aspect, and the green line indicates the incision on the lateral aspect. (B) Two months postoperative result after using the w-shaped technique.

both in the appearance of the edge of the labia minora and in the neurovascular preservations of the labia. In comparison with the w-shaped method, there is less postoperative discomfort in patients treated by the de-epithelialized technique. The postoperative pain duration is usually less than 1 week, and the swelling disappears in 2 weeks.

References

1. Capraro VJ. Congenital anomalies. *Clin Obstet Gynecol.* 1971;14:988.
2. Radman HM. Hypertrophy of the labia minora. *Obstet Gynecol.* 1976;48(suppl 1):78S.
3. Kato K, Gotoh M, Tanaka J, Kondo A, Namiki Y, Saitoh M. Hypertrophy of labia minora in myelodysplastic women. *Urology.* 1988;31:294.
4. Hodgkinson DJ, Hait G. Aesthetic vaginal labioplasty. *Plast Reconstr Surg.* 1984;74:414.
5. Alter GJ. A new technique for aesthetic labia minora reduction. *Ann Plast Surg.* 1998;40:287.
6. Choi HY, Kim KT. A New method for aesthetic reduction of labia minora (the deepithelialized reduction labioplasty). *Plast Reconstr Surg.* 2000;105:419–422.
7. Maas SM, Hage JJ. Aesthetic labia minora reduction [letter]. *Ann Plast Surg.* 1998;41:685. ?3
8. Giraldo F, Gonzales C, Nichol DE, Haro F. Central wedge nympectomy with a 90 degree Z plasty for aesthetic reduction of the labia minora. *Plast Reconstr Surg.* 2004;113:1820–1825. ?4
9. Rouzier R, Louise-Sylvestre C, Paniel BJ, Haddad B. Hypertrophy of labia minor, experience with 163 reductions. *Am J Obstet Gynaecol.* 2000;182:35–40. ?5